

BOSTWICK'S
PLASTIC & RECONSTRUCTIVE

Breast Surgery

THIRD EDITION



GLYN E. JONES

Technologic Advances in Breast Surgery

Glyn E. Jones, MD

- Indocyanine Green Fluorescence Imaging of Skin Perfusion
- SPY Camera
- Perforator Mapping With CTA or MRA

INDOCYANINE GREEN FLUORESCENCE IMAGING OF SKIN PERFUSION



The expanded use of flap techniques in breast reconstruction has led to the need for reliable assessment of flap skin perfusion to allow the incorporation of the most well-perfused portions of the flap into a reconstruction to prevent delayed healing. The increasing use of perforator flaps and the realization that cross-midline tissues carry an increasing risk of poor perfusion in certain patients has expanded the need for these techniques. Further, the use of skin-sparing mastectomy has resulted in greater potential for mastectomy skin flap loss postoperatively. This complication can be devastating when an implant or expander has been used for immediate reconstruction, because it is strongly associated with implant infection and loss of the reconstruction.

In the past, fluorescein injection has been most widely used to assess skin perfusion. Although this technique is inexpensive and correlates reasonably well with skin viability, it is prone to problems, such as the following:

- Anaphylaxis
- Single dosing
- Inability to repeat the examination
- Difficult interpretation in darker-skinned patients
- The need for an ultraviolet light source

The ideal skin perfusion assessment technique should be repeatable, easily interpreted regardless of skin color, accurate, and cost effective.

Indocyanine green dye fluorescence appears to fulfill these criteria. The identification of poorly vascularized skin intraoperatively can save patients, surgeons, and hospitals a great deal of time, money, and resource allocation at a time when medical costs worldwide are under intense scrutiny.

Basic Science

Indocyanine green is an iodinated dye that fluoresces under infrared light. It can be safely injected intravenously, but is not recommended in patients with iodine allergies. Its half life in the circulation is 4 to 5 minutes, allowing rapid redosing as needed for multiple studies intraoperatively. Indocyanine green is eliminated through the biliary tract and can be used to visualize the common bile duct as a consequence. For the purposes of breast surgery, a dose of 10 mg (4 ml) is injected per image. Imaging is possible within 8 to 10 seconds after the dye has entered the circulation through a peripheral line, or 5 seconds when administered through a central line.

Imaging

Indocyanine green dye fluoresces when exposed to infrared laser light. The fluorescence can be detected by a thermal imaging infrared camera to a depth of 3 mm into the tissue being imaged. The data are collated by computer and visualized as a gray scale infrared image in real time. Software analysis of the image is then possible to quantify relative perfusion values throughout the imaged tissues. The imaging duration is only 60 seconds, allowing rapid decision-making by the operative team. Subsequent computer analysis and numeric quantification of flow takes an additional 2 to 4 minutes after image capture.

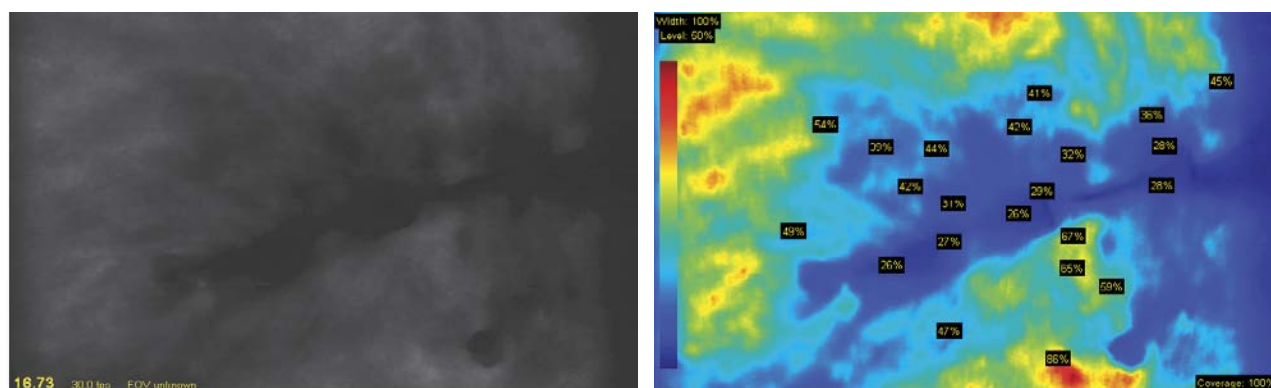
SPY CAMERA

Effective software imaging and image analysis are provided by the Novadaq SPY system (Novadaq Technologies). The device consists of a mobile cart that contains the camera/laser housing attached to an articulated arm, computer screen and CPU with keyboard. The screen is touch-screen sensitive. A sterile sleeve and vials of indocyanine green are provided as a separate pack on a case-by-case basis. The dye is reconstituted with saline solution for intravenous injection and has to be flushed with 10 ml of intravenous fluid by the anesthesiologist after injection into the access site. Because the device is portable, it can be used either intraoperatively or at bedside in a patient's room if necessary.



Imaging Process

The camera head and articulated arm are draped with a sterile sleeve intraoperatively. The computer is booted up and, on initiation of the study, patient demographics are entered into the accompanying database using an on-screen menu. When imaging is desired, the camera, draped in a sterile plastic sleeve, is brought into the field on its articulated arm. The camera aperture is opened and the head is positioned over the operative field. An on-screen height indicator strip guides the surgeon to the correct focal distance of the lens above the patient's body surface and allows activation of the equipment. Positioning either too close to or too far from the patient's surface prevents activation. Once active, the daylight image is turned off, and the laser imaging is activated. The dose of indocyanine green (10 mg) is injected intravenously, and an 8- to 10-second count is performed, followed by imaging, which starts via on-screen activation of the laser. All room lights should be turned off, because ambient light can influence the interpretation of quantified data by the software program. Image acquisition takes 60 seconds for a complete study. The study is saved and can be evaluated quantitatively within 2 to 3 minutes. Studies are stored on the hard drive but can be burned to a DVD as DICOM or mpeg images.



Once stored, the image can be converted from gray scale to color by the software to demonstrate “hot” and “cold” spots, which correlate with relatively well and poorly perfused areas of tissue, respectively. This is illustrated in these images, showing a mastectomy skin flap in a smoker before expander insertion. In gray scale imaging, the darker gray to black an image, the less well it is perfused, and whiter areas represent relatively good perfusion. In color, red areas are better perfused than those indicated by dark blue to purple tones. In these images, the poorly perfused skin adjacent to the mastectomy incision is dark in gray scale and blue in color. The poorly perfused skin was resected. Newer iterations of the software have incorporated a quantitative component to assist surgeons in evaluating the data. This has consisted of calibrating the image by selecting the best-

perfused area and denoting it as 99%, after which the program calculates relative values of the rest of the image compared with the best-perfused selection. These are presented as percentage values of the area assigned the 99% value and can be seen by simply touching the screen at any selected point, at which site a relative value immediately appears as a percentage.

Concerns about the calibration being influenced by ambient light reflection from surrounding drapes, for example, have led to further refinements that enable surgeons to calibrate both a zero perfusion value (for example, a dark drape adjacent to the field) as well as a 100% value within the best-perfused area of patient tissue on the scan. All relative values are then recalculated against these parameters to provide a more accurate estimate of percentage perfusion. These values are not absolutes and do not represent flow in cubic centimeters per gram of tissue or cubic centimeters per minute. They simply denote whether or not a given piece of tissue has perfusion and how it compares with the best-perfused area within the scan.

The goal of such imaging is to provide the surgeon with a more accurate guide to the resection of poorly perfused tissue, when necessary, than would be evident with clinical evaluation alone. The goals are to reduce postoperative morbidity associated with tissue necrosis or wound healing problems and to help surgeons identify perforators that, for example, perfuse the largest area of a flap and do so most rapidly.

Clinical Applications

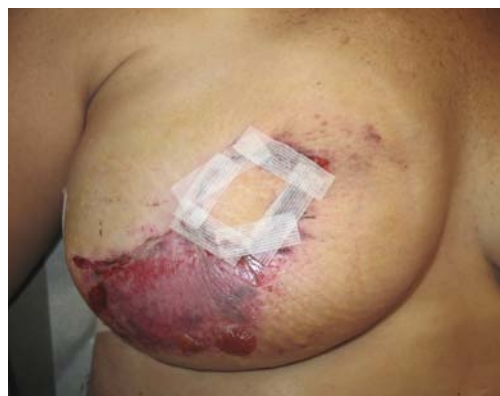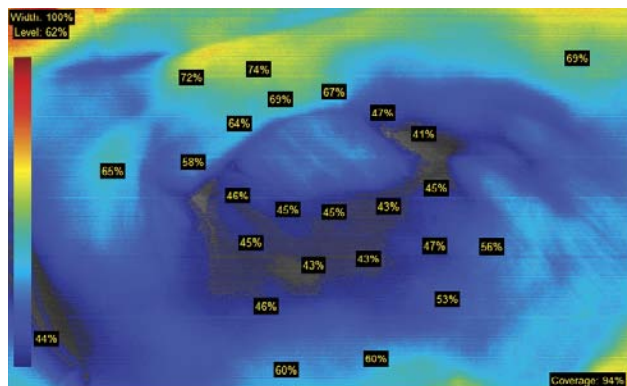
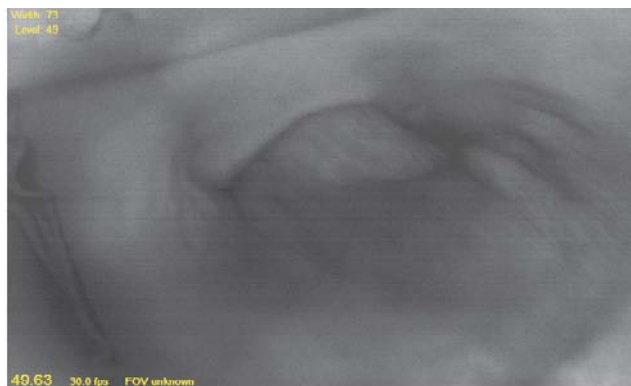The following clinical applications within the field of plastic surgery have been found to be most valuable:

1. Evaluating the viability of skin-sparing mastectomy flaps before immediate reconstruction
2. Evaluating the perfusion of soft tissue flaps used in reconstruction
3. Determining the rate of perfusion within a given flap surface from multiple perforators to assist with selecting the perforator that provides the fastest and most extensive inflow into a flap

Evaluation of Mastectomy Skin Flap Viability

One of the most common questions I (G.E.J.) am asked concerning immediate reconstruction of skin-sparing mastectomy defects is how I assess skin flap viability to reduce the morbidity of postoperative skin necrosis, whether after flap or expander-implant-based reconstruction. Ideally, TRAM or DIEP flaps placed beneath a mastectomy flap are deepithelial-

placed. The device was then inserted and expanded to only 100 cc, and intraoperative imaging was repeated. Satisfactory perfusion was noted up to the cut edge of the skin, and closure was performed without further inflation of the expander. The patient went on to heal uneventfully. The implant was gradually expanded to 500 cc, and an expander-implant exchange was performed.

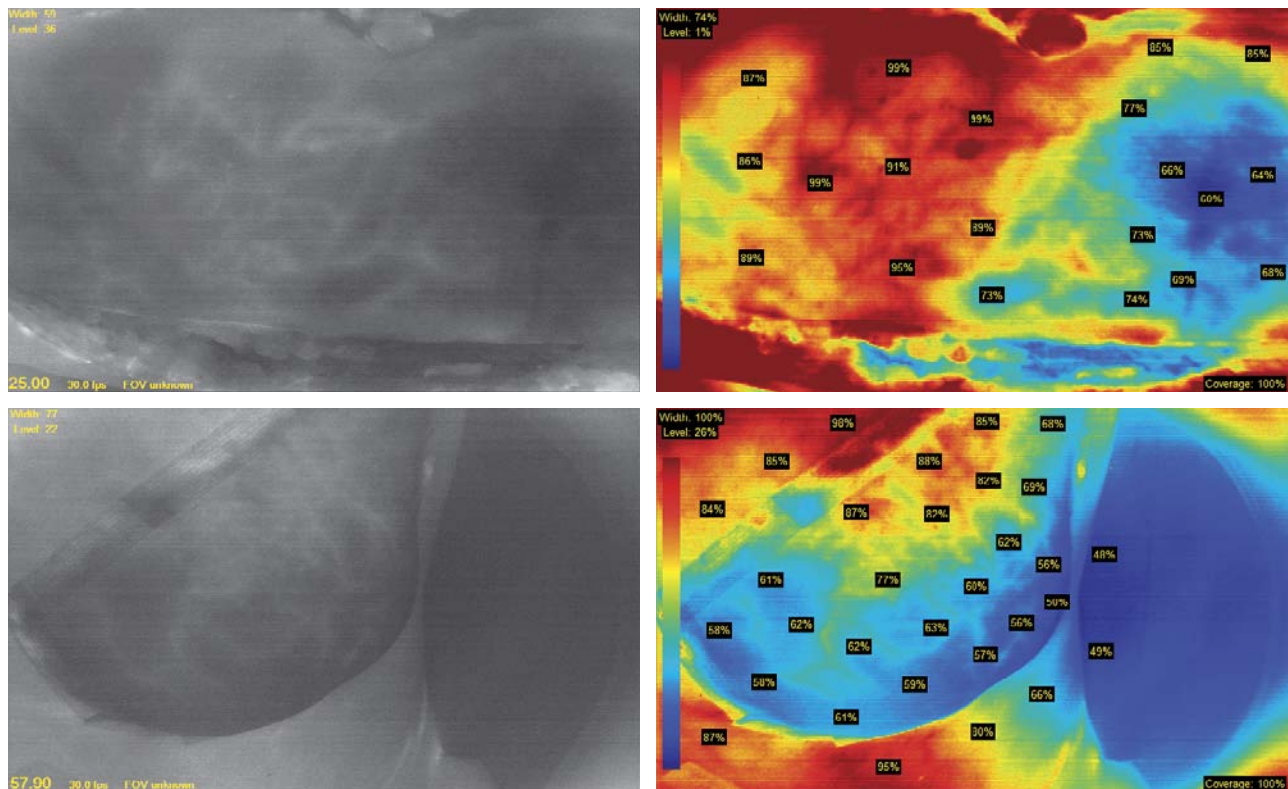


This 52-year-old woman had been diagnosed with carcinoma of the right breast, and a skin-sparing mastectomy with TRAM flap reconstruction was planned. She had a 30-pack-year history of smoking and had recently stopped smoking in preparation for surgery. The mastectomy skin flaps and the abdominal flap were imaged with the SPY camera before inset.

Although the TRAM flap had excellent perfusion in zones I through III clinically and on imaging, the indocyanine green perfusion map suggested that the inferolateral mastectomy skin flap was marginally perfused. The clinical impression was one of excellent capillary refill in this area. She also bled from the cut surface of the skin edge. We decided to override the SPY imaging data based on clinical findings, because resection of the affected skin would compromise TRAM flap shaping and breast aesthetics. Postoperatively, the TRAM flap healed uneventfully without clinical evidence of fat necrosis. Unfortunately, the inferolateral mastectomy skin demarcated in a pattern identical to that identified intraoperatively by the SPY image; debridement of the skin was performed in the office. The underlying TRAM flap was healthy. This case dramatically illustrates how well the SPY image perfusion map correlates with areas of subsequent skin necrosis, regardless of clinical impressions.

DETERMINING THE EXTENT OF FLAP PERFUSION

Indocyanine green perfusion of flap viability has been a valuable adjunct in determining the extent of reliable perfusion of flaps such as the TRAM flap in breast reconstruction. Flap zonal perfusion as described by Hartrampf, and subsequently Holm and colleagues provided a means of deciding which areas of a TRAM flap may or may not be reliably transferred for breast reconstruction. *Indocyanine green mapping provides an accurate assessment of flap perfusion which correlates remarkably well with subsequent flap survival in the clinical setting.* Those areas appearing dusky on the initial 1-minute study do not perfuse reliably when transferred to the chest and should be debrided. Clinical experience in situations where clinical impressions have been allowed to override the SPY images have led to poor outcomes.



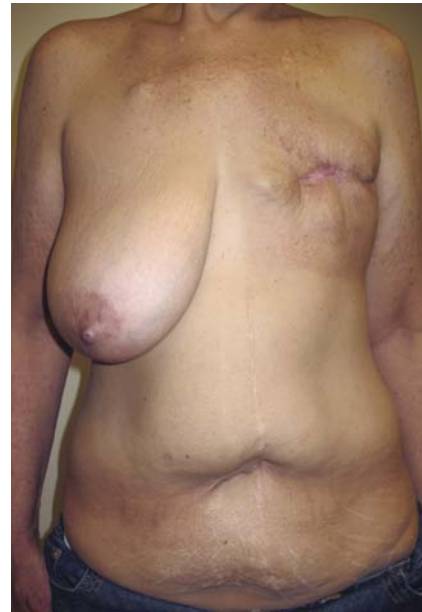These images are of a middle-aged nonsmoker who had delayed reconstruction after a left mastectomy and radiation to the chest wall. A free TRAM flap was planned. During dissection, the superficial inferior epigastric vessels had been divided, and they were noted to be large. Once raised, the flap exhibited a degree of congestion, despite draining through the deep inferior epigastric system. When the flap was imaged, it was found to have poor cross-midline perfusion; the perfusion values were lower than expected for a nonsmoker with no risk factors. After transfer to the chest,

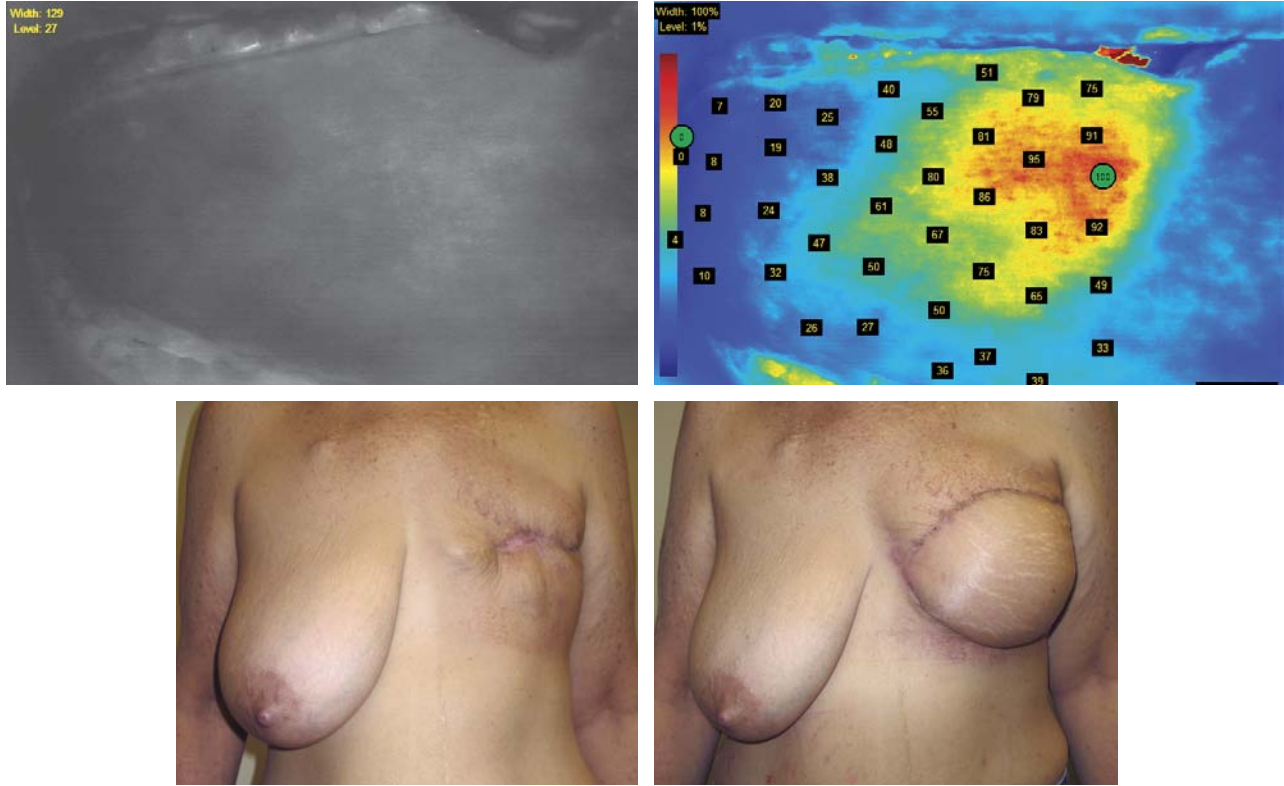
imaging of the flap was performed again and revealed areas of decreased perfusion along the inferior rim, which subsequently required debridement and closure. It was thought that this flap was probably superficial inferior epigastric vein (SIEV)–dominant for its venous outflow, resulting in a degree of venous congestion that led to tissue necrosis along the inferior rim of the flap.

DETERMINING PERFORATOR INFLOW RATES

Perforator mapping with CTA or MRA has become a very widely used modality to save time intraoperatively. The procedure determines where perforators are located within the abdominal pannus, and a good radiologist can calibrate the diameter of these vessels and map the exact location in centimeters from the umbilicus. What mapping cannot do is determine how fast a given perforator creates a cutaneous blush, which may be indicative of its size and relative vascular inflow or perfusion pressure. Obviously, the larger and more robust a perforator's inflow, the better it would be as a choice for use in a perforator-based flap. Currently, the most accurate way of testing this phenomenon is to isolate the desired potential perforator choices and then clamp each one in turn to see if its contribution to flap flow is significant or not. I have found that watching the speed at which a given perforator starts perfusing the flap can provide valuable data indicating the relative perfusion pressure and territory of supply of a particular vessel.

This 60-year-old woman with a 50-pack-year history of smoking had a left mastectomy and postoperative radiation therapy. Her mastectomy site developed a recurrent seroma during and after radiation therapy, requiring surgical drainage. This was complicated by delayed healing over a 6-month period. One year later, she underwent reconstruction. Her latissimus donor site was of poor quality and very tight. A muscle-sparing free TRAM flap was planned; a perforator mapping CTA was not performed.





At operation, SPY camera imaging showed several large perforator “blooms” on the right side. Exploration revealed two large perforators in line with one another, the largest 3 mm in diameter and the smaller 2 mm in diameter. An intraoperative decision was made to perform a DIEP flap based on these two vessels. A successful outcome was achieved with anastomosis to the left internal mammary vessels. She is shown before right breast reduction for symmetry with a well-healed, soft DIEP flap.

Outcomes

This instrumentation has not been available for wide general use until recently. Data are only now starting to appear in the literature. Our own experience with this device has been immensely encouraging. We have performed imaging of 106 patients in two hospitals during the past 15 months. Thirty-four patients had 49 TRAM flaps as either pedicle, free, or DIEP variants (eight free and 41 pedicle); 25 patients had 68 expander or implant insertions; four had latissimus dorsi flaps; and 21 patients had breast reductions. The breast reduction group was added to evaluate the technology for assessment of nipple-areola complex viability during breast reduction. The remaining patients had assorted lower extremity flaps for reconstruction. Of all the studies, 76% were performed in my own patients (G.E.J.). In all patients, clinical evaluation of skin flap perfusion was matched with

SPY images. Resection of all questionable tissue was performed in all but three patients with TRAM flaps in whom I thought clinical assessment suggested adequate perfusion. No clinical fat necrosis developed in the patients in whom debridement was performed in conjunction with the SPY data. In three pedicle TRAM flaps, tissue was preserved on clinical grounds, despite a suggestion of poor perfusion on SPY imaging. In all three patients, necrosis developed in the areas predicted by indocyanine green perfusion imagery. The correlation was 100%. Of 68 expander reconstructions, skin was preserved on clinical grounds, despite SPY imaging suggesting poor perfusion in three patients with a history of smoking. All three patients developed necrosis, requiring subsequent debridement and closure, with one woman ultimately losing her expander because of excessive skin tension over a completely deflated expander. Correlation was again 100% accurate.

Most reported series of skin-sparing mastectomy necrosis range from 12% to 15% in nonsmokers to as high as 25% to 30% in smokers. In our series, clinically evident skin necrosis occurred in three of 49 TRAM flaps (6%); all three were positively identified by the SPY images but overridden by clinical judgment that proved incorrect. In all three cases, the complication could have been averted had the SPY data been followed instead. Of 68 expander insertions, three patients developed necrosis requiring minor or major revisions, and one patient lost her expander as a result. In all three cases (4.3%), SPY imaging suggested poor perfusion and skin was preserved on clinical grounds, resulting in skin loss postoperatively. If the SPY data had been followed instead of clinical judgment, skin necrosis would have been reduced to 0%.

It is clear from these data that indocyanine green perfusion in skin flaps and autologous tissue flaps is a remarkably sensitive, accurate, and specific test for skin perfusion. By following the perfusion map, the surgeon can accurately predict which skin is likely to necrose, and debridement should be performed accordingly. It is difficult to place one's faith implicitly in this technology when we have been trained to evaluate skin perfusion clinically for decades. However, after more than 16 months of experience with this device, I am convinced of its accuracy and have learned through personal experience to rely more on the SPY data than my own estimation of skin viability.

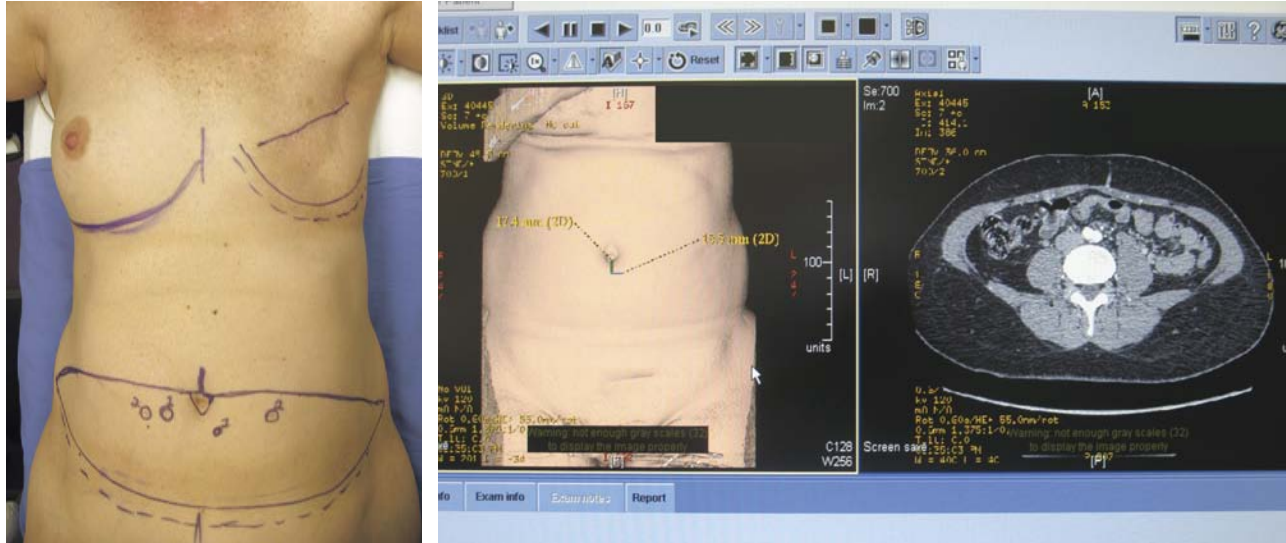
Issues remain surrounding the interpretation of quantitative assessment of the SPY data. The initial, first-generation software required selection of the area of best perfusion, and then calculated the rest of the image as a percentage of this value. It appeared to work well. Questions remained, however: What value is compatible with skin survival of 25% or 35% and how did risk factors affect it, such as prior smoking, radiation, obesity, or breast size? The second-generation software attempts to deliver more accuracy by using a “100%” cursor over the best-perfused area and a “0%” cursor over nonperfused areas, such as a surgical drape. The calculations are then performed relative to these two end points and may be more representative of actual flow rates. Again, what values are tolerable in low-risk versus high-risk patients? Much more data must be analyzed before we can come to any firm conclusions with respect to quantification.

The refinement of hardware to take advantage of the indocyanine green perfusion technique has developed to a new level of sophistication. In our own experience, we now have the potential to reduce postoperative morbidity from skin necrosis to almost zero. This represents a real advance, which will improve patient outcomes and contribute to reduced medical costs at a time when health care expenditure is under increasing scrutiny.

PERFORATOR MAPPING WITH CTA

The increasing use of perforator flaps in reconstructive surgery in general and breast reconstruction specifically has led to the need to identify suitable perforators preoperatively for clinical use. Although a flap may have several feeding vessels, it is preferable to base a flap on large vessels of 1.5 to 3 mm caliber. The preoperative localization and calibration of such vessels can significantly reduce intraoperative dissection time. Until recently, color duplex ultrasound was the most reliable technique available.

In recent years, technology has advanced to the point that radiologists are now able to localize these vessels reliably with either CT- or MRI-based angiography. A CTA study performed a few days before the planned flap procedure allows the radiologist to calibrate the diameter of potential vessels as well as accurately localize them on the skin surface. Markers can be placed together with precise measurements from fixed landmarks, such as the umbilicus.



This patient is shown with a perforator map marked on her abdominal wall preoperatively by the radiologist after performing CTA 2 days before surgery. He calibrated the largest of several perforators just inferior and lateral to the umbilicus on the left side. The technique is remarkable for its accuracy, although it does add a layer of cost to an already expensive procedure.

Not only has CTA increased the reliability of perforator use, it has also facilitated rapid dissection down onto the apparently dominant vessel without the need to spend time evaluating smaller vessels within the flap. When combined with the use of technology such as the Novadaq SPY camera or similar technology, the dominance and location of a particular vessel can be determined with precision.

Conclusion

Technologic advances in imaging modalities have made significant contributions to our operative procedures in breast reconstruction. With the increasing emphasis on outcomes-based data, it is encouraging to find products that are influencing our results in a positive fashion, both intraoperatively and postoperatively. These advances have been derived from close cooperation between surgeons who are seeking new technologies and research scientists capable of developing the technology for clinical use. The future holds great potential for the expanded use of advanced imaging devices.

➤ CLOSING THOUGHTS ➤

Biomedical science is a rapidly advancing discipline that has brought numerous technologic changes to surgery. Although breast surgery has been a relatively underdeveloped area of inquiry, recent technologic advances in imaging have directly affected our field. Recent advances in quantitative imaging of vascular inflow to flaps have tremendously enhanced our ability to assess intraoperative vascularity within mastectomy skin flaps and autologous reconstructions. These advances not only improve patient outcomes, but appear to improve patient morbidity and reduce medical costs by decreasing complications.

Teaching Points

- Indocyanine green mapping provides an accurate assessment of flap perfusion that correlates remarkably well with subsequent flap survival.
- CTA has increased the reliability of perforator use, and has facilitated rapid dissection down to the apparently dominant vessel.

BIBLIOGRAPHY

- Holm C, Mayr M, Höfter E, et al. Perfusion zones of the DIEP flap revisited: a clinical study. *Plast Reconstr Surg* 117:37, 2006.
- Losken A, Styblo TM, Schaefer TG, et al. The use of fluorescein dye as a predictor of mastectomy skin flap viability following autologous tissue reconstruction. *Ann Plast Surg* 61:24, 2008.
- Moyer HR, Carlson GW, Styblo TM, et al. Three-dimensional digital evaluation of breast symmetry after breast conservation therapy. *J Am Coll Surg* 207:227, 2008.